



**Article Type:** Case Report

## **Thoracoscopic Neuroprotective Phrenotomy; A New Surgical Technique For Idiopathic Incurable Chronic Hiccups**

<sup>1</sup>Bayrakçi Onur, MD, Department of Thoracic Surgery, Gaziantep City Hospital, Türkiye

**Corresponding Author:** Bayrakçi Onur, MD, Department of Thoracic Surgery, Gaziantep City Hospital, Türkiye

**Conflict of interest:** Nil

This is an Open Access article that uses a funding model which does not charge readers or their institutions for access and distributed under the terms of the Creative Commons Attribution License (<http://creativecommons.org/licenses/by/4.0>).

### **Abstract**

**Background:** The hiccups are caused by contractions of the diaphragm muscle, which causes the end of inspiration due to premature closure of the epiglottis. Hiccups, which also cause contraction of the intercostal muscles, are involuntary and spasmodic. In this study, we aimed to present the surgical treatment with thoracoscopic neuroprotective phrenotomy in a case of intractable hiccups that continued almost every second for 6 months without any pathology in etiology, without any response to drug treatments.

**Method:** The patient was dually intubated with intravenous anesthetic agents (propofol) without the use of a neuromuscular blocking drugs. Bispectral index monitoring was done to monitor the depth of anesthesia and ensure patient safety. Intraoperative neuromonitoring was done before the surgery began. During the surgery, the phrenic nerve pathway was repeatedly stimulated, monitored, and recorded. In this way, flow delays and amplitudes in the entire phrenic nerve and pathological findings in the nerve were determined. The nerve structure where electrophysiological pathology was detected was bipolar ablated. During the surgery, active

contractions of the diaphragm muscle were observed with a neurostimulator after the procedure. Before the surgery was terminated, it was confirmed that the diaphragm was functioning normally during spontaneous breathing.

**Presentation of Case:** A 32-years-old female patient admitted to the clinic with complaints of hiccups that started suddenly after eating and hadn't subsided for 6 months. There was no additional disease, trauma or drug use in her anamnesis. No pathological findings were detected in radiological cranial, cervical, thoracic and abdominal examinations and, no pathological findings were detected in physical examination. There was no response to drug treatments and separate left and right phrenic nerve blocks, respectively. The patient's respiratory rate per minute was measured as 16, but the number of hiccups was measured as 48 during ward follow-up. While she took a total of approximately 23,040 breaths a day, she experienced 69,120 hiccups. It was very dramatic and affected the patient's entire life, including eating, sleeping and breathing. Diaphragmatic movements were examined in detail with diaphragmatic ultrasound and fluoroscopy. A new technique we discovered was aimed at protecting the respiratory

nerves. Surgical treatment was done with right VATS neuroprotective phrenotomy. She was followed up in the postoperative ward for 7 days. No hiccups were seen. A chest X-ray revealed a normal level diaphragm and no respiratory distress. The patient, who had no complaints at the 2-month post-discharge follow-up.

**Conclusion:** If there is no response to drug treatments and phrenic nerve blockade in cases of idiopathic persistent chronic hiccups, treatment can be provided with neuroprotective frenotomy, a new surgical technique that aims to protect the respiratory nerve.

**Keywords:** Hiccups, Muscle, Respiratory Nerve, Steroids

### Introduction

The hiccups are caused by contractions of the diaphragm muscle, which causes the end of inspiration due to premature closure of the epiglottis. Hiccups, which also cause contraction of the intercostal muscles, are involuntary and spasmodic<sup>1</sup>. Involuntary intercostal muscle contractions can also cause pain. Hiccups can occur occasionally, although rarely, in every person. It only requires treatment when it is bothersome and persistent. The prevalence of hiccups is not clearly known, but they are more common in children and adult males. Hiccup attacks are generally constant for each individual and occur at a rate of 4-60 per minute<sup>2</sup>. A hiccup is defined as persistent if it lasts longer than 48 hours, and intractable if it lasts longer than 2 months<sup>3</sup>. Treatment of hiccups should be directed at the cause if it can be identified (e.g. infections can be treated with antibiotics, brainstem lesions with steroids and radiotherapy). Persistent hiccups are usually idiopathic. When the world medical literature was examined in detail, no scientific study was found on the surgical treatment of hiccups by preserving the phrenic nerve, the

respiratory nerve, with electrophysiological detection. In this study, we aimed to present the surgical treatment with thoracoscopic neuroprotective phrenotomy in a case of intractable hiccups that continued almost every second for 6 months without any pathology in etiology, without any response to drug treatments.

### Method

It is known in the literature that pathology related to the phrenic nerve may play a role in the etiology of hiccups. Therefore, it is essential to examine every point where the phrenic nerve passes anatomically in the cranial and extracranial regions. Radiologically, it was demonstrated that there is no organic pathology that can affect the phrenic nerve in the brain, brainstem, cervical region, thorax and abdominal structures. In addition, considering that hiccups might be of psychological origin, a psychiatric examination was performed on the patient by a specialist physician.

Diaphragmatic movements were examined with fluoroscopy during breathing and holding breath. Which side caused abnormal asymmetric movements and if bilateral, the rates of each side were determined separately. Diaphragmatic movement during hiccups was then examined by ultrasonography, and physical examination findings were confirmed by fluoroscopic evaluation.

No radiological, biochemical, neurological or psychological pathology was detected in the patient. It has been reported in the literature that drugs such as antipsychotics, anticonvulsants, antidepressants, anxiolytics, antifoaming and prokinetic agents, proton pump inhibitors, steroids and central muscle relaxants may be beneficial<sup>1</sup>. Our patient had used most of these medications, but stated that there was no reduction in her

hiccup complaints. At this stage, the hiccup complaint was accepted permanent and incurable<sup>3</sup>.

After physical examination, ultrasonography and fluoroscopic examination, the side with asymmetric diaphragm movement was determined. Selective phrenic nerve blockade (lidocaine and/or steroid) was done with ultrasonography-guided radiofrequency (RF) assistance from the localization where the phrenic nerve anatomically passes in the determined cervical region<sup>4</sup>.

### Thoracoscopic neuroprotective phrenotomy

A decision for surgery was made for persistent and incurable hiccups that persisted for at least 2 months, with no neurological, psychiatric, biochemical or radiological pathology detected, and hiccup complaints that did not regress with drug treatments and did not respond to phrenic blockade.

The patient was dually intubated with intravenous anesthetic agents (propofol) without the use of a neuromuscular blocking drugs. Bispectral index (BIS) monitoring was done to monitor the depth of anesthesia and ensure patient safety<sup>5</sup>. The BIS value was maintained between 40 and 60 (normal depth of anesthesia) throughout the surgery (Figure 1). No muscle relaxants were used to assess spontaneous or neurostimulator-induced movements of the diaphragmatic muscle.

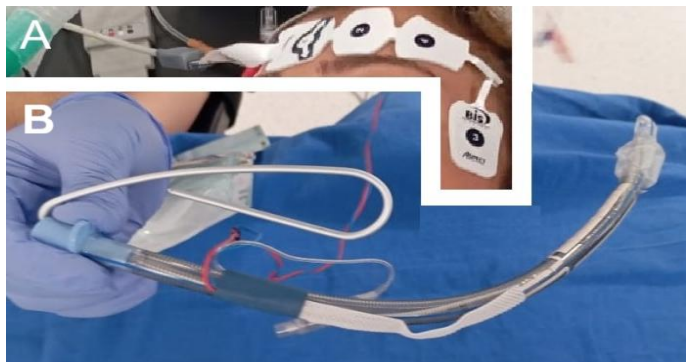


Figure 1: A. Bispectral index (BIS) probes B. Receiver probe in the intubation tube

Intraoperative neuromonitoring (IONM) was done before the surgery began<sup>6</sup>. IONM is known to offer a significant opportunity to salvage at-risk nerve tissue before irreversible damage occurs. In addition to monitoring, which involves repeatedly stimulating a nerve pathway during surgery, certain methods allow for the stimulation and recording of critical anatomical structures before surgery begins<sup>7</sup>. The phrenic nerve is the motor nerve of the diaphragm and is known to have a very important place in respiration. Therefore, neuromonitoring was preferred to preserve the main phrenic nerve. The classical location where the phrenic nerve passes is adjacent to the anterior scalenius muscle<sup>8</sup>. These localization records were used as a basis for neuromonitoring and motor stimulation was done cranially (Figure 2).

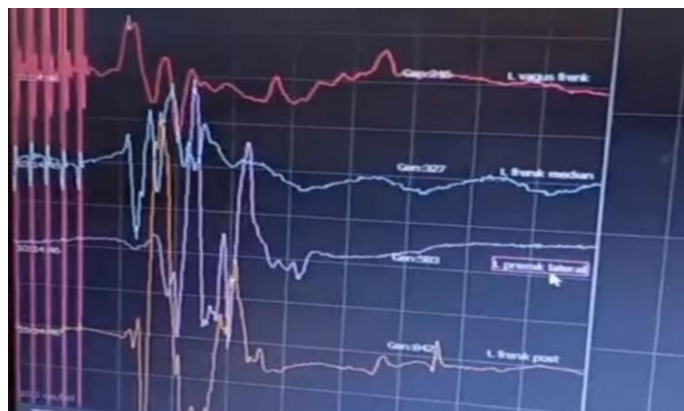


Figure 2: Recordings of phrenic nerve motor stimulus on the intraoperative neuromonitoring

The thorax was entered through the 5th intercostal space in the anterior axillary line using the Uniportal Video-assisted thoracoscopic surgery (VATS) method. The phrenic nerve was followed from apical to basal to its entry point into the diaphragm. It was confirmed that there was no fibrosis, inflammation, adhesion or retraction, or mass pathology that could affect the phrenic nerve. The phrenic nerve was freed from the surrounding tissues with millimetric dissections around the

pericardium. At the point where the nerve entered the diaphragm, the diaphragmatic pleura was separated by dissection. In this area, the phrenic nerve was seen to give off four branches extending posteriorly, medially, anterolaterally and laterally (Figure 2). Spontaneous electrical activity in the diaphragmatic muscle was recorded on the monitor using a conductive strip. Then, for measurement purposes, separate conductive strips were attached to the points where the four branches of the nerve coursed in the diaphragm muscle (Figure 3). Motor evoked potentials (MEPs) were obtained by stimulating the primary motor cortex (0-2 mV). Recordings obtained separately from the four branches of the phrenic nerve were compared. It was found that the amplitude was minimized in the medial and anterolateral branches and there was a delay compared to the others (the time it takes to reach after being stimulated).

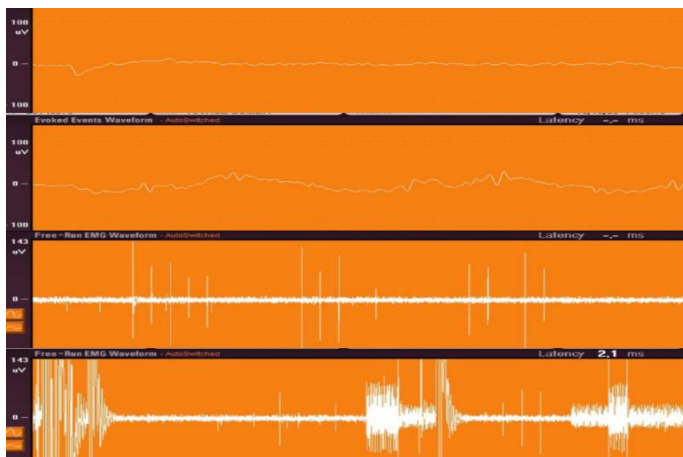


Figure 3: Intraoperative neurostimulator recordings of the phrenic nerve

Bipolar ablation was applied to these two branches and their ends were clipped. Then, the main phrenic nerve and its four branches were stimulated separately with a manual neurostimulator (0-3 mV). Diaphragm movements were seen and recorded. BIS values were checked, the depth of sedation was reduced, and the patient's spontaneous breathing was waited to return. The

procedure was concluded when it was observed that the diaphragm participated in spontaneous breathing fully and in a timely manner.

### Presentation of Case

A 32-years-old female patient admitted to the clinic with complaints of hiccups that started suddenly after eating and hadn't subsided for 6 months. There was no additional disease, trauma or drug use in her anamnesis. Etiological radiological, biochemical and other examinations have been performed by the gastroenterology clinic in our hospital. No pathological findings were detected in radiological cranial, cervical, thoracic and abdominal examinations and, no pathological findings were detected in physical examination. However, hiccups were observed that continued almost every second and severely affected eating, drinking, sleeping, and even breathing. Due to this complaint, the patient used various medications such as proton pump inhibitor (pantoprazole), metoclopramide, spasmolytic, myorelaxant, chlorpramozin, anxiolytic, baclofen drugs for a period of 6 months. She stated that there was no decrease in her hiccup complaints. As a result of the evaluations, it was accepted as idiopathic resistant chronic hiccup. Right and left selective phrenic nerve blockade was done respectively by the Algology clinic in our hospital. The patient admitted to surgical clinic as her complaints continued.

She was followed up with medical drugs in the Thoracic Surgery Department ward. In addition to the medications the patient used, there was no response to chlorpormazine infusion and baclofen treatment. The patient's respiratory rate per minute was measured as 16, but the number of hiccups was measured as 48 during ward follow-up. While she took a total of approximately 23,040 breaths a day, she experienced 69,120 hiccups. It was very

dramatic and affected the patient's entire life, including eating, sleeping and breathing. Fluoroscopic and ultrasonographic examination seen asymmetric movement of the right diaphragm (Figure 4).

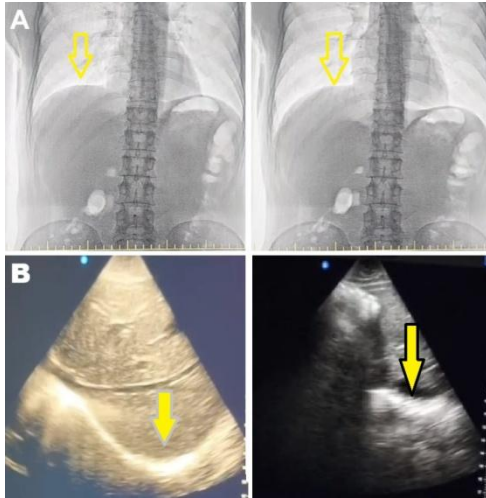


Figure 4: A. Asymmetric movement of the diaphragm on fluoroscopy B. Diaphragmatic image on USG

A decision was made to perform surgery for the patient whose complaints continued dramatically despite drug treatments and phrenic nerve blocks. Right Uniportal VATS neuroprotective frenotomy and bipolar ablation were done (detailed 2.5. in method and procedure). A nerve-sparing procedure was performed with BIS and IONM (Figure 5).

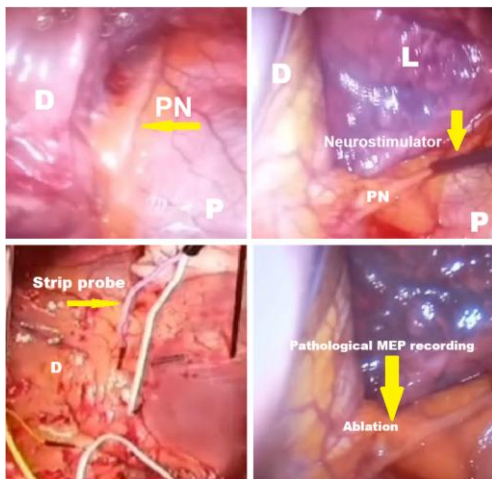


Figure 5: Phrenic nerve motor evoked potential measurement and neurostimulation

\*D: Diaphragm, P: Pericardium, L: Lung, PN: Phrenic Nerve, MEP: Motor evoked potential

Intraoperative video confirmed that the patient's diaphragm movement was natural during spontaneous breathing. She was followed up in the postoperative ward for 7 days. No hiccups were seen. A chest X-ray revealed a normal level diaphragm and no respiratory distress. The patient, who had no complaints at the 2-month post-discharge follow-up (Figure 6).

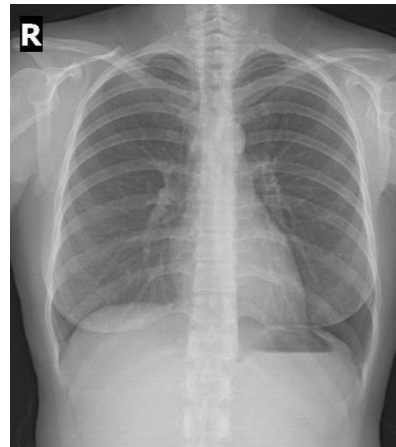


Figure 6: Postoperative 2nd month chest radiography

### Discussion

The scientific explanation for hiccups is unclear. One theory suggests that an amorphous nerve network, associated with the vagus nerve, phrenic nerve, and brainstem, serves as the "hiccup center." Damage or stimulation of these structures results in hiccups due to an imbalance between inspiratory and expiratory nervous circuits<sup>9</sup>. The etiology of hiccups also includes gastrointestinal, central nervous system disorders, metabolic disorders, psychogenic disorders, and medications<sup>10</sup>.

In this case, there were complaints of hiccups that started spontaneously, even though she had no complaints, no illness, and no medication use. Traditional methods such as holding one's breath, drinking water, or eating lemon were of no benefit. The high number of hiccup attacks

had a serious negative impact on the patient. Numerous examinations were conducted on etiology. Brain magnetic resonance imaging (MRI) was performed to detect a cranial pathology, brain computed tomography (CT) angiography was performed to exclude cranial vascular pathology, cervical MRI was performed to exclude cervical pathology, thoracic CT was performed to evaluate mediastinal structures, and abdominal CT was performed for intra-abdominal exclusion. Endoscopic examination was done for gastrointestinal system evaluation. Echocardiography was done to exclude a possible cardiac and pericardial pathology. Although the patient had no complaints, she was examined by a psychiatrist to rule out a psychogenic etiology. She had no neurological symptoms but was still evaluated by a neurologist. Interestingly, no cranial, cervical, thoracic, abdominal, gastrointestinal, neurological or psychological pathological findings were detected. Therefore, the patient's diagnosis was accepted as idiopathic intractable chronic hiccup.

When the literature search was performed, antipsychotics (chlorpromazine, haloperidol), anticonvulsants (valproic acid), defoaming and prokinetic agents, peppermint, proton pump inhibitors, baclofen, nifedipine, methylphenidate, midazolam, lidocaine, dexamethasone and sertraline treatments were recommended<sup>1</sup>. Of these recommended medications, only baclofen reduced the patient's symptoms by approximately 10-15%. No response was observed with any of the other recommended medications.

Literature reviews were conducted for treatment methods other than medication. It has been reported that hiccups can be treated with selective phrenic nerve block<sup>11</sup>. First, ultrasound-guided left phrenic blockade was performed by the algology clinic. No response was received. After a

while, right phrenic blockade was performed. There was a significant decrease in her complaints in less than 1 day, but the hiccup attacks continued in the same way.

The patient's observations and treatments were continued in the thoracic surgery ward. Ultrasound was done to examine diaphragmatic movements during hiccup attacks. Asymmetric movements of the right diaphragmatic muscle were suspicious. Diaphragmatic movements were examined under fluoroscopy while active hiccups continued. Asymmetrical movement was observed in the right diaphragmatic muscle. Surgical procedures such as clipping, laser application, and ligation of the phrenic nerve have been reported to be used in the treatment of chronic hiccups<sup>12</sup>. However, since the phrenic nerve, which is the motor nerve of the diaphragm, also provides respiration, respiration would be negatively affected in these procedures. The patient's breathing and diaphragmatic muscle needed to continue normal function.

The patient was taking a total of approximately 23,040 breaths per day and experiencing 69,120 hiccup attacks. The aim was to provide surgical treatment for the patient and to protect the phrenic nerve, which is the nerve of respiration. For this reason, a new method, the Thoracoscopic neuroprotective phrenotomy technique, was discovered, which is expressed in the methods section in the article. With this method, which detects intraoperative electrophysiological changes in the phrenic nerve, the part of the nerve where pathology was detected could be treated, and the main phrenic nerve was preserved, allowing the patient to continue breathing normally.

### **Conclusion**

If there is no response to drug treatments and phrenic nerve blockade in cases of idiopathic persistent chronic

hiccups, treatment can be provided with neuroprotective frenotomy, a new surgical technique that aims to protect the respiratory nerve.

### References

1. Cornelius J.W. Managing hiccups. *Can Fam Physician* 2011 Jun; 57(6):672-675.
2. Marinella MA. Diagnosis and management of hiccups in the patient with advanced cancer. *J Support Oncol*. 2009;7(4):122-7. 130.
3. Smith HS, Busracamwongs A. Management of hiccups in the palliative care population. *Am J Hosp Palliat Care*. 2003;20(2):149-54.
4. Xijian K, Yin Zhu W, Hua Z. Successful termination of persistent hiccups via combined ultrasound and nerve stimulator-guided singular phrenic nerve block: a case report and literature review. *J Int Med Res* 2023 Dec 2;51(12): 03000605231216616.
5. Surbhi M, Jashvin P, Sheldon G, Joseph M.H, Ankit J. Bispectral Index. *StatPearls* [Internet]. Last Update: Nov 6,2023.
6. Adkins G.B, Pescador M.A, Koht A.H, Gosavi S.P. Intraoperative neuromonitoring in intracranial surgery. *British Journal of Anaesthesia*. 2024;24 (5):173-182.
7. Aldana E, Álvarez López-Herrero N, Benito H. Consensus document for multimodal intraoperative neurophysiological monitoring in neurosurgical procedures. *Basic Fundamentals*. *Rev Esp Anesthesiol Reanim (Engl Ed)*. 2021; 68:82-98.
8. Krieger LM, Krieger A J. Intercostal nerve to phrenic nerve transfer: an effective means of resuscitating the diaphragm in patients with high cervical spine injuries. *Plast Reconstr Surg*. 2000 Apr;105(4):1255-61.
9. Regnard C. Dysphagia, dyspepsia and hiccup. In: Doyle D, Hanks G, Cherny NI, Calman K, editors. *Oxford textbook of palliative medicine*. 4th ed. New York, NY: Oxford University Press; 2010. pp. 499-512.
10. Smith HS. Hiccups. In: Walsh TD, Caraceni AT, Fainsinger R, Foley KM, Glare P, Goh C, et al., editors. *Palliative medicine*. New York, NY: Saunders; 2009. pp. 894-8.
11. Steven H.R, Geert J van G, Harald C.R, Mathieu J.G, Gert J.S. Ultrasound-guided continuous phrenic nerve block for persistent hiccups. *Reg Anesth Pain Med* 2010 Sep-Oct;35(5):455-7.
12. Jung R.Y, Yum D.K, Soo I.Y, Myung E.C. Phrenic Nerve Clipping in a Stroke Patient with Intractable Hiccup: a Case Report. *Brain Neurorehabil*. 2018 Mar;11(1):e2. English. Published online Mar 20, 2018.