



Patient Specific Implant for Post Traumatic Secondary Orbital Deformity Correction: A Case Report

¹Dr. Pradeep Christopher, ²Dr. Yaseer Arafat, ³Dr. Aswathy Haridas, ⁴Dr. Vandana Shenoy, ⁵Dr. Gayathri Gopi, ⁶Dr. Amar Singh

¹Professor and HOD, Department of Oral and Maxillofacial Surgery, Dr. MGR Educational and Research Institute (Thai Moogambigai Dental College and Hospital), Chennai, India

²Consultant, Department of Oral and Maxillofacial Surgery, Dr. MGR Educational and Research Institute (Thai Moogambigai Dental College and Hospital), Chennai, India

^{3,6}PG Student, Department of Oral and Maxillofacial Surgery, Dr. MGR Educational and Research Institute (Thai Moogambigai Dental College and Hospital), Chennai, India

^{4,5}Professor, Department of Oral and Maxillofacial Surgery, Dr. MGR Educational and Research Institute (Thai Moogambigai Dental College and Hospital), Chennai, India

Citation of this Article: Dr. Pradeep Christopher, Dr. Yaseer Arafat, Dr. Aswathy Haridas, Dr. Vandana Shenoy, Dr. Gayathri Gopi, Dr. Amar Singh, “Patient Specific Implant for Post Traumatic Secondary Orbital Deformity Correction: A Case Report.” IJMSAR – October – 2024, Vol. – 7, Issue - 5, Page No. 23-29.

Copyright: © 2024, Dr. Aswathy Haridas, et al. This is an open access journal and article distributed under the terms of the creative commons attribution noncommercial License. This allows others to remix, tweak, and build upon the work non commercially, as long as appropriate credit is given and the new creations are licensed under the identical terms.

Corresponding Author: Dr. Aswathy Haridas, PG Scholar, Department of Oral and Maxillofacial Surgery, Dr. MGR Educational and Research Institute (Thai Moogambigai Dental College and Hospital), Chennai, India

Type of Publication: A Case Report

Conflicts of Interest: Nil

ABSTRACT

Introduction

Orbital fractures remain a significant challenge in reconstructive surgery due to their complex anatomy and potential for long-term functional and aesthetic deficits. Traditional techniques often involve prefabricated implants that may require intraoperative manipulation. Patient-specific implants (PSIs) offer a better alternative to address these challenges.

Case Presentation

A 25-year-old female presented with post-traumatic left orbital enophthalmos and diplopia. Imaging revealed a complex orbital fracture with extraconal fat herniation. A PSI was designed using virtual surgical planning and 3D printing. The implant was successfully placed, resolving enophthalmos and diplopia.

Discussion

PSIs offer several advantages over traditional implants, including precise anatomical fit, improved functional outcomes, and enhanced aesthetics. The use of virtual surgical planning allows for meticulous preoperative planning and intraoperative guidance. While PSIs have shown promising results, challenges such as cost and limited post-implantation modifications need to be considered.

Conclusion

This case demonstrates the efficacy of PSIs in secondary orbital reconstruction. Future research is needed to evaluate the long-term outcomes and cost-effectiveness of PSIs compared to traditional techniques.

Keyword

Secondary orbital deformity, Orbital dystopia, Orbital reconstruction, Patient specific implant.

INTRODUCTION

Orbital fractures constitute a significant portion of craniomaxillofacial trauma, representing approximately 10-25% of all injuries and often results in significant functional and aesthetic sequelae^{1,2}. While primary surgical intervention aims to restore form and function, secondary deformities can persist, significantly impacting patients' quality of life. Despite significant advancements in reconstructive surgical techniques, orbital fractures continue to pose substantial challenges due to complex anatomical structures, diverse injury patterns and the need to restore the volume loss. Traditional reconstructive methods for orbital volume and contour restoration have relied on standardized prefabricated titanium plates, meshes and grafts. Pre-fabricated orbital implants are designed based on the average orbital

shape and may offer adequate reconstruction in less complex cases³. Secondary orbital reconstruction is complicated by several factors such as distorted anatomical relationships due to previous trauma or surgical interventions, the presence of existing implants that require removal, extensive scarring, and late-onset soft tissue changes like fat atrophy⁴. Pioneering work in orbital reconstruction utilizing patient-specific implants (PSIs) was introduced by Williams and Revington⁵. Since then, multiple clinical studies have substantiated the efficacy of PSIs in orbital reconstruction. PSI offers precise anatomical fit, improved functional outcome, enhanced esthetic results and potential for long term stability particularly in post-traumatic orbital deformity correction. Several biomaterials have been used to create these implants include titanium, methylmethacrylate, hydroxyapatite, porous polyethylene, and polyetheretherketone (PEEK)⁶. Here we present a case report of post traumatic secondary deformity correction of orbit using virtual surgical planning and titanium patient specific implant (PSI).

CASE PRESENTATION

A 25-year-old female presented with aesthetic concerns involving the left eye following a road traffic accident sustained two years prior. The patient had undergone a craniotomy and open reduction and internal fixation (ORIF) under general anesthesia during the initial management of her injuries. Clinical examination revealed facial asymmetry centered on the left orbital region, with pronounced enophthalmos, hypoglobus, diplopia, and orbital dystopia in the affected eye. Visual acuity and ocular motility were preserved. A high-resolution computed tomography (CT) scan of facial bones with a slice thickness of

1.5/2mm including three-dimensional reconstruction, was acquired to assess orbital volume and bony defects. Imaging findings demonstrated previously operated fractures involving the left frontal bone, left superolateral orbital rim, anterior wall of the maxillary sinus, and symphysis menti along with an in situ

osteosynthesis device. Additionally, a blowout fracture of the left orbit with herniation of extraconal fat into the left maxillary sinus was identified. No evidence of muscle entrapment was observed (Fig 1). Based on these findings, a secondary residual deformity of the left orbit was diagnosed.

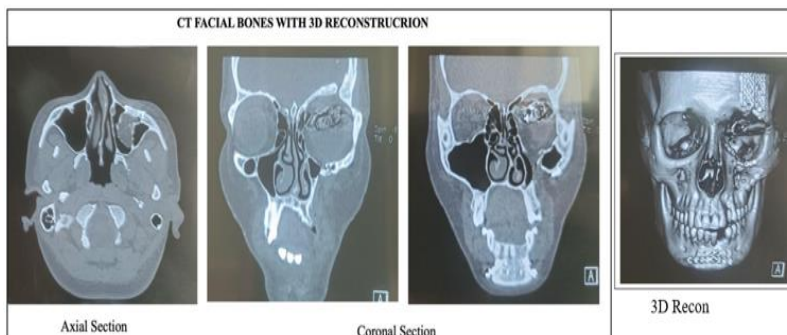


Fig 1- CT Facial Bones with 3D reconstruction

Virtual surgical planning (VSP) was performed using specialized software to analyze the CT DICOM data. The volume noted on the left orbit was 28.7 cubic centimeter and on the right orbit(normal) was 26.7 cubic centimeter. The contralateral normal orbit was mirrored to establish a reference volume (26.7 cubic centimeter) for the affected side. A three-dimensional (3D) model of the orbital defect was generated, allowing for precise measurement and assessment of the required implant volume.

A patient-specific titanium implant was designed using CAD software based on the VSP data. The implant was meticulously crafted to match the contours of the orbital defect and restore the desired orbital volume antero-posteriorly to correct enophthalmos and supero-inferiorly to correct hypoglobus. Advanced imaging techniques were employed to ensure accurate representation of the patient's anatomy in the implant design.

Under general anesthesia, transconjunctival incision and lateral cantholysis incision was performed. Layer wise dissection was carried along the retroseptal plane and the orbital floor was exposed, revealing the extent of the bony defect. The previously placed hardware was removed. The prefabricated titanium PSI was carefully secured in place using 1.5 *6mm screws. Gentamicin wash was given over the prosthesis and the surgical wound was closed in layers using 6-0 vicryl and 6-0 ethilon. The patient tolerated the surgery well with minimal postoperative complications. Postoperative imaging confirmed accurate implant placement and restoration of orbital volume. Diplopia resolved completely within a day. The patient exhibited significant improvement in enophthalmos and hypoglobus with satisfied functional and aesthetic outcome (Fig 2)

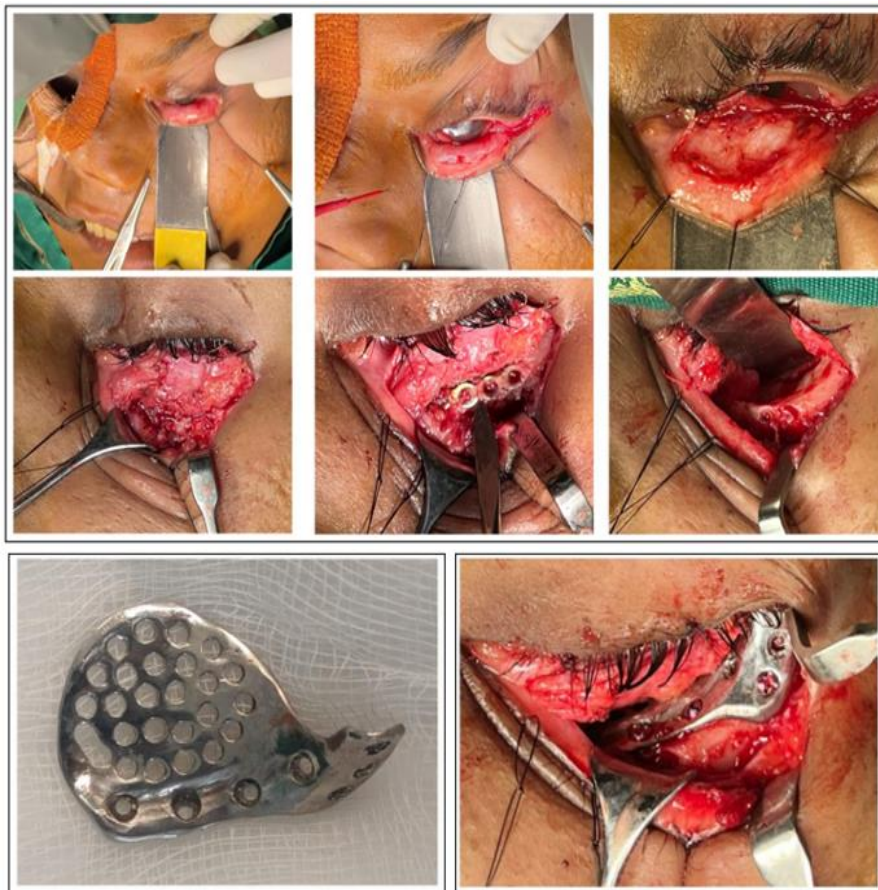

Fig 2 - Intraoperative photographs

DISCUSSION

Orbital reconstruction presents a formidable challenge for surgeons given the intricate anatomy, limited space, and critical role of the eye in human life⁷. The primary goals of managing orbital injuries encompass three key areas: (1) repairing orbital wall defects by restoring orbital volume, (2) reconstructing the normal orbital contour while considering individual anatomical variations, and (3) correcting ocular globe position⁸. Traditional methods of repair by using preformed implant with various materials (titanium, polytetrafluoroethylene, silicone, polyethylene, etc.) have been advocated. Precise positioning of these materials within the orbital cavity is often difficult to achieve, frequently contributing to suboptimal treatment results. While standard titanium meshes

have not been shown to yield inferior functional outcomes compared to patient-specific implants (PSIs), they necessitate extensive intraoperative manipulation and are associated with increased blood loss as per studies by Zelinski et al⁹

In our case, the patient had undergone primary treatment with titanium mesh however the clinical outcome was suboptimal and the patient had significant enophthalmos and diplopia. As per literature, post-traumatic enophthalmos could be due to bony orbital enlargement, displacement of the trochlea, scarring within the orbital tissues, incomplete repair of orbital fractures, malpositioned orbital contents, orbital fat atrophy, and weakened ligamentous support^{10,11}. The management of post-

traumatic enophthalmos is widely considered challenging. While a correlation between diplopia and inferior rectus muscle entrapment has been proposed, Tessier et al. reported a low incidence of true muscle entrapment in their cohort¹². Instead, they attributed diplopia primarily to oculomotor dysfunction. Moreover, these authors emphasized the role of orbital fat loss in the development of post-traumatic enophthalmos, rather than subsequent fat atrophy. Secondary orbital reconstruction is notably more complex than primary repair due to factors such as scar tissue, bone deformities, soft tissue irregularities, and the presence of existing implants or hardware¹³.

The integration of computer-assisted surgery (CAS) has significantly advanced surgical practices, impacting both preoperative planning and intraoperative execution. This progress encompasses the utilization of stereolithography for constructing 3D anatomical models and the implementation of real-time surgical navigation and guidance systems. Notably, CAD/CAM technologies have facilitated a higher degree of patient-specific customization. Within the realm of orbital reconstruction, the capacity to produce fully customized patient-specific implants (PSIs) that precisely mirror the intricate orbital anatomy represents a notable advancement over traditional surgical approaches.

A volumetric analysis done by Cohen et al of patients with late-onset enophthalmos who had not undergone surgery revealed that a decrease in orbital fat combined with an enlarged orbital cavity exacerbated the condition¹⁴. This suggests that restoring bone volume alone may be insufficient, and additional volume replacement is often necessary. Patient-specific implants (PSIs) can address this by providing

the required volume to compensate for the loss of orbital fat. In our case there was increase in volume in affected orbit and this was accurately corrected by mirroring the volume of the unaffected side. PSI effectively corrected enophthalmos and led to complete resolution of diplopia in this case report. Patient-specific implants (PSIs) have been demonstrated to offer greater precision compared to standard implants in orbital floor reconstruction as found by Zimmer et al¹⁵. While there were no significant differences in eyeball position or mobility between the two groups, the use of PSIs resulted in approximately 15% reduction in surgical time. Additionally, Kand et al. reported that virtual planning and the application of customized implants led to enhanced facial symmetry¹⁶.

Titanium meshes have been utilized in this surgical domain since the 1990s. Research indicates that titanium meshes integrate seamlessly with soft tissue, and there is no evidence suggesting increased inflammation in patients with sinus communication. A titanium mesh PSI was used in our case and a cohort study by Schreurs et al. evaluated 23 patients undergoing secondary post-traumatic orbital reconstruction with patient-specific implants (PSIs). Significant improvements in enophthalmos, diplopia, and hypoglobus were observed postoperatively compared to preoperative conditions¹⁷. A meta-analysis by Kotecha et al found that although there is a prevailing inclination towards patient-specific implants (PSIs), meta-analyses have not revealed statistically significant differences in primary outcomes when compared to traditional methods¹⁸.

A transconjunctival approach with lateral cantholysis was the approach used in this case. Schlittler et al.

emphasized the significance of a preseptal transconjunctival approach in orbital surgery incorporating lateral canthotomy/cantholysis for all patients¹⁹. This approach preserved the integrity of the orbital septum and its contents.

The fabrication of patient-specific implants (PSIs) necessitates a planning and manufacturing process, typically spanning one to two weeks. The cost of a PSI is influenced by its size and complexity, generally exceeding that of conventional implants. While PSIs offer advantages, post-implantation modifications are limited. However, this may change in the future with possible real-time design and intraoperative manufacturing. In our case the fit of the titanium PSI was adequate and did not require any modification during the time of placement.

Computer-aided virtual planning, coupled with the creation and placement of patient-specific implants (PSIs), has significantly enhanced the functional outcome for this patient with satisfactory esthetic results for secondary orbital reconstructions. PSIs facilitate orbital correction and reconstruction without the need for additional bone cuts or grafts.

CONCLUSION

Patient-specific implants (PSIs) have emerged as a promising modality in the management of secondary orbital deformities. By offering precise anatomical restoration, improved functional outcomes, and potential benefits in surgical efficiency, PSIs have the potential to become the standard of care for secondary orbital reconstruction. While the benefits of PSIs are evident, challenges such as cost and limited opportunities for post-implantation modification warrant consideration. As technology continues to evolve, it is anticipated that PSIs will play an

increasingly pivotal role in optimizing patient care for complex orbital reconstructions.

REFERENCES

1. Scherer M, Sullivan WG, Smith DJ et al (1989) An analysis of 1,423 facial fractures in 788 patients at an urban trauma center. *J Trauma* 29:388–390. <https://doi.org/10.1097/00005373-198903000-00020>
2. Erdmann D, Follmar KE, Debruijn M et al (2008) A retrospective analysis of facial fracture etiologies. *Ann Plast Surg* 60:398–403. <https://doi.org/10.1097/SAP.0b013e318133a87b>
3. Strong EB, Fuller SC, Wiley DF, Zumbansen J, Wilson MD, Metzger MC. Preformed vs intraoperative bending of titanium mesh for orbital reconstruction. *Otolaryngol Head Neck Surg* 2013; 149:60–6
4. Kim JS, Lee BW, Scawn RL, Korn BS, Kikkawa DO. Secondary orbital reconstruction in patients with prior orbital fracture repair. *Ophthal Plast Reconstr Surg* 2016;32 (6):447–51
5. Williams JV, Revington PJ. Novel use of an aerospace selective laser sintering machine for rapid prototyping of an orbital blowout fracture. *Int J Oral Maxillofac Surg* 2010;39(02):182–184
6. Patient specific implants in orbital reconstruction: A pilot study☆ Larissa A. Habiba, Michael K. Yoon.
7. Patel N, Kim B, Zaid W. Use of virtual surgical planning for simultaneous maxillofacial osteotomies and custom polyetheretherketone implant in secondary orbito-frontal reconstruction: importance of restoring orbital volume. *J Craniofac Surg* 2017;28(02):387–390

8. Mommaerts MY, Büttner M, Vercruyssen H Jr, Wauters L, Beerens M. Orbital wall reconstruction with two-piece puzzle 3d printed implants: technical note. *Craniofacial Trauma Reconstr* 2016;9(01):55–61
9. Zieliński R, Malińska M, Kozakiewicz M. Classical versus custom orbital wall reconstruction: selected factors regarding surgery and hospitalization. *J Craniofacial Surg* 2017;45(05):710–715
10. Strong EB: Orbital fractures: Pathophysiology and implant materials for orbital reconstruction. *Facial Plastic Surgery* 30: 509, 2014.
11. Clauser L, Galiè M, Pagliaro F, Tieghi R: Posttraumatic enophthalmos: Etiology, principles of reconstruction, and correction. *Journal of Craniofacial Surgery* 19: 351, 2008.
12. Tessier P: Complications of facial trauma: principles of late reconstruction. *Annals of plastic surgery* 17: 411, 1986.
13. Cai EZ, Koh YP, Hing ECH, Low JR, Shen JY, Wong HC, Sundar G, Lim TC. Computer-assisted navigational surgery improves outcomes in orbital reconstructive surgery. *J Craniofac Surg* 2012;23(5):1567–73.
14. Cohen LM, Habib LA, Yoon MK. Post-traumatic enophthalmos secondary to orbital fat atrophy: a volumetric analysis. *Orbit Amst.Neth.* 2020;39(5):319–324. <https://doi.org/10.1080/01676830.2019.169160>.
15. Zimmer, R.M.; Ellis, III E.; Sanchez Ancieto, G.; Schramm, A.; Wagner, M.; Grant, M.P.; Cornelius, C.P.; Strong, E.; Rana, M. et al. A prospective multicenter study to compare the precision of posttraumatic internal orbital reconstruction with standard performed and individualized orbital implants. *J. Craniofacial Surg.*, 44:1485- 97, 2016.
16. Kand, Y.F.; Liang, J.; He, Z.; Zhang, L.; Shan, X.F. & Cai, Z.G. Orbital floor symmetry after maxillectomy and orbital floor reconstruction with individual titanium mesh using computer-assisted navigation. *J. Plast. Reconstr. Aesthetic. Surg.*, 73:337-43, 2020.
17. R. Schreurs, C. Klop, P. J. J. Gooris, T. J. J. Maal, A. G. Becking, L. Dubois: Critical appraisal of patient-specific implants for secondary post-traumatic orbital reconstruction. *Int. J. Oral Maxillofac. Surg.* 2022; 51: 790–798. 2021
18. Kotecha S, Ferro A, Harrison P, Fan K. Orbital reconstruction: a systematic review and meta-analysis evaluating the role of patient-specific implants. *Oral Maxillofac Surg.* 2023 Jun;27(2):213-226. doi: 10.1007/s10006-022-01074-x. Epub 2022 May 20. PMID: 35589881; PMCID: PMC10234907.
19. Schlittler F, Vig N, Burkhard JP, et al. What are the limitations of the non-patient-specific implant in titanium reconstruction of the orbit? *Br J Oral Maxillofac Surg.* 2020;58: e80–e85.